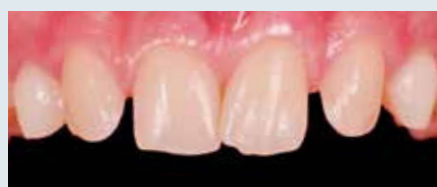
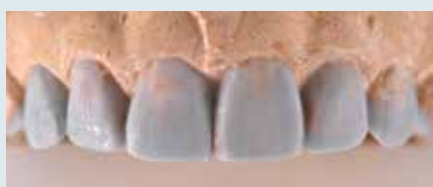
The Predictability of No-Prep Composite Veneers

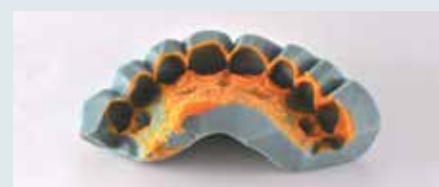
Composite veneers provided a 19-year-old patient with a minimally invasive, highly esthetic treatment. Before the restoration process began, the patient whitened his teeth with Opalescence Go® take-home whitening trays. Multiple Mosaic® composite shades were then used to mimic surrounding dentition and address proper occlusion and function of the six upper anterior teeth. Final polishing was completed two weeks after the procedure; the waiting period allowed for rehydration of the tooth and restoration so adjustments to the shade and anatomy could be made as needed.



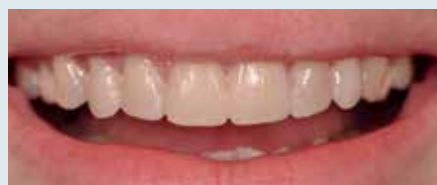1. Note the presence of both deciduous upper canines and many dental diastemas due to the agenesis of the permanent counterparts.



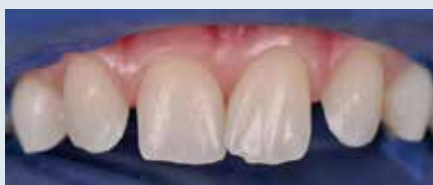2. Final wax-up, following proper esthetic proportions and occlusion requirements.



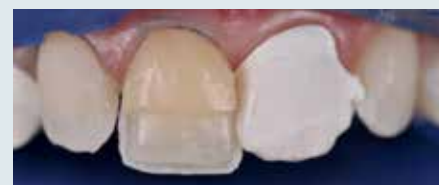3. Mock-up silicone guide.



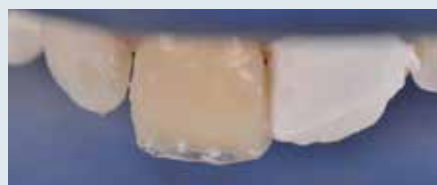5. Intraoral mockup made with ExperTemp® temporary crown and bridge material.



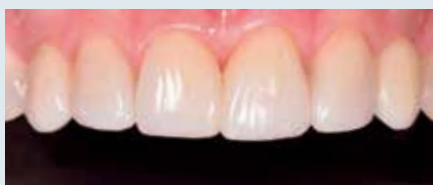6. Modified rubber dam isolation. Note the highly reflective white enamel.



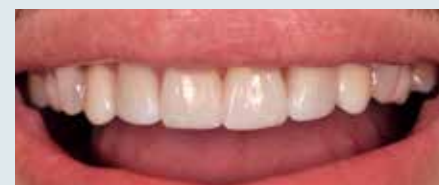7. Layering of the palatal shell (Enamel White) and dentin (A3 on the cervical followed by A2 on the remaining buccal surface).



8. Opaque White and Enamel Trans shades are placed along the incisal edge, mimicking the information-rich incisal region of younger patients.



9. Completed restoration of all six upper anterior teeth. Last layer of composite was Enamel White, which was also used for the palatal shell.



10. Integration between restoration and natural tooth structures resulting in a more harmonic smile.



"The mockup with ExperTemp made all the difference in the patient's decision to have treatment. That, and also knowing there would be absolutely no harm done to the teeth made it an easy choice...no prep at all!"

—Dr. Rafael Beolchi
São Paulo, Brazil

